

Anaesthetic Considerations in Emergency Lower Segment Caesarean Section in Preeclamptic Parturient with Neurofibromatosis: A Case Report

CHARMI HITENBHAI SHAH¹, UPASNA VINEET BHATIA², SARA MARY THOMAS³

(CC) BY-NC-ND

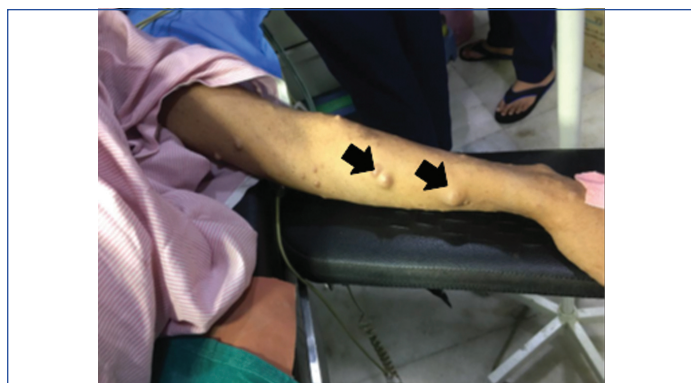ABSTRACT

Neurofibromatosis type I (NF1) is an autosomal dominant genetic disorder characterised by multiple cutaneous manifestations and potential systemic involvement that can complicate anaesthetic management, especially in obstetric patients. This case report describes the anaesthetic management of a 27-year-old primigravida with NF1 and preeclampsia who presented to obstetric department for emergency cesarean delivery due to foetal distress. The patient displayed classic NF1 features including café-au-lait spots and multiple cutaneous neurofibromas. Airway assessment revealed Mallampati Grade III classification without palpable oropharyngeal masses. Given the emergency situation and potential airway challenges, general anaesthesia was selected using rapid sequence induction with propofol and succinylcholine. Anaesthesia was maintained with oxygen, nitrous oxide, sevoflurane, and atracurium, with fentanyl administered after delivery. The patient maintained stable haemodynamics throughout the procedure despite preeclampsia with baseline blood pressure of 140/100 mmHg. Despite the potential for difficult airway management and cardiovascular complications in patients with NF1, the perioperative period was uneventful with successful mother and baby outcomes. This case emphasises the importance of thorough preoperative assessment, anticipation of potential complications, and a tailored anaesthetic approach in managing parturients with NF1, particularly in emergency scenarios complicated by preeclampsia.

Keywords: Anaesthetic management, Cafe-au-lait spots, High blood pressure

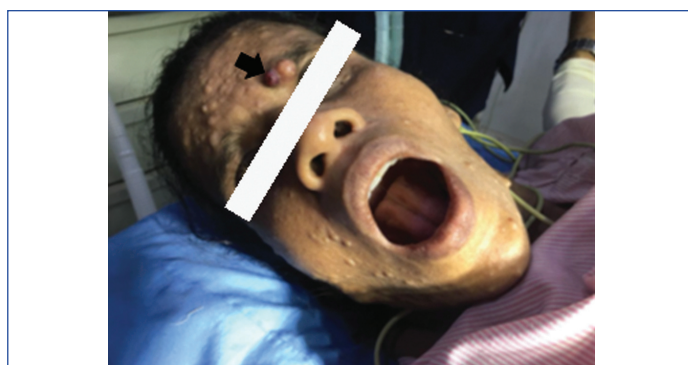CASE REPORT

A 27-year-old primigravida, measuring 154 cm in height and weighing 68 kg, presented at 37 weeks' gestation for an emergency Lower Segment Cesarean Section (LSCS). The patient had been diagnosed with NF1 approximately 10 years earlier, based on the presence of multiple café-au-lait spots and cutaneous neurofibromas [Table/Fig-1]. The patient also presented with characteristic neurofibromas on the face [Table/Fig-2].



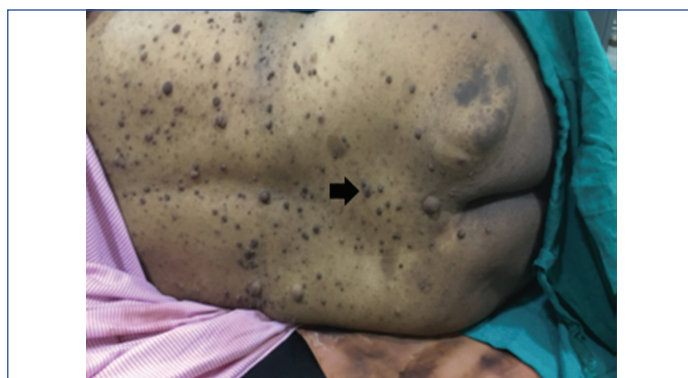
[Table/Fig-1]: Café-au-lait spots and neurofibroma on arm.

As shown in [Table/Fig-3], the patient had additional café-au-lait spots and neurofibromas distributed on her body. Her medical history was significant for preeclampsia, and she was currently receiving Tablet Labetalol 100 mg twice daily to manage her blood pressure. There was no prior history of surgery, known drug allergies, or other comorbidities apart from preeclampsia and NF1. In this case, the diagnostic criteria for NF1 were met as the patient exhibited more than six café-au-lait spots and multiple cutaneous neurofibromas, with a family history suggestive of the disorder, though no plexiform neurofibromas or Lisch nodules were documented. Detailed family history revealed that her father was diagnosed with NF1 and exhibited

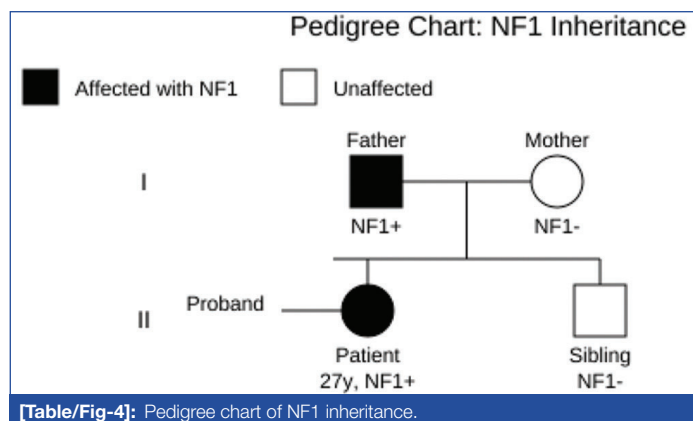


[Table/Fig-2]: Neurofibromas on the face.

similar cutaneous manifestations, while her mother was unaffected. The patient had one sibling who did not show any symptoms of NF1. A pedigree chart was created to illustrate the inheritance pattern [Table/Fig-4]. History was carefully obtained, emphasising the chronicity of her NF1 manifestations and the current obstetric complications.

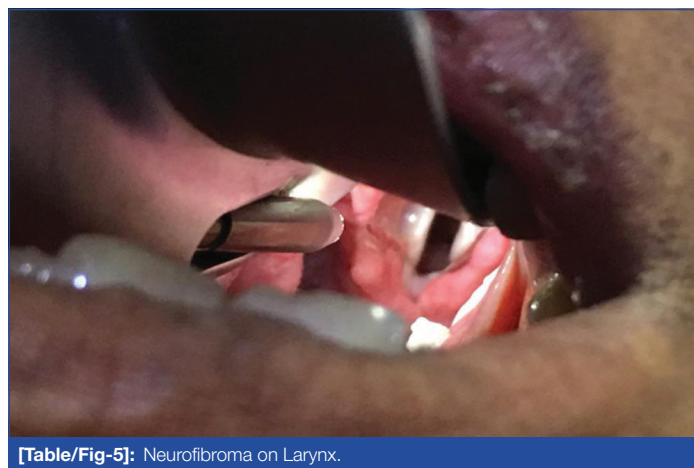

[Table/Fig-3]: café-au-lait spots and neurofibromas on body.



Vital signs recorded prior to surgery revealed a pulse rate of 96 beats per minute, blood pressure of 140/100 mmHg, respiratory rate of 20 breaths per minute, and an oxygen saturation (SpO₂) of 100% on room air, with a normal body temperature. Physical examination was conducted in a systematic manner. General examination was done; bilateral pitting oedema was noted in the lower extremities, indicative of fluid retention often seen in preeclamptic patients.

Airway evaluation was performed: the patient had a mouth opening equivalent to three finger breadths, and although the Mallampati score was Grade III, suggesting a potentially challenging airway, there was no palpable mass in the oral cavity. Neck extension and flexion were normal, thereby reducing the anticipated difficulty in intubation. [Table/Fig-5] illustrates a neurofibroma on the larynx, which is a potential airway concern in patients with NF1.



Laboratory investigations were obtained to evaluate the patient's overall status and readiness for surgery. The results are summarised in [Table/Fig-6]:

Test (Reference range for females)	Observed laboratory investigations
Haemoglobin: 12-15 gm/dL	12.3 gm/dL
WBC count: 4,000-11,000/mL	9,400/mL
Platelet count: 150,000-400,000/ μ L	382,000/ μ L
Sodium: 135-145 mEq/L	136 mEq/L
Potassium: 3.5-5.1 mEq/L	4.8 mEq/L
Chloride: 98-107 mEq/L	100 mEq/L
ECG: Normal sinus rhythm	Within normal limits
Proteinuria: Negative/Trace	++
Random Blood Sugar: 70-140 mg/dL	100 mg/dL

[Table/Fig-6]: Laboratory investigations.

Anaesthetic management was done as following: After obtaining written informed consent, the patient was prepared for surgery being nil by mouth for six hours. Considering the urgency of the case in the setting of foetal distress and the potential airway challenges posed by NF1, general anaesthesia was chosen. The obstetric evaluation

included confirmation of full-term cephalic presentation, with foetal heart sounds ranging from 70 to 90 beats per minute on non-stress testing. Vaginal examination revealed a two-finger loose cervical dilatation with early effacement, absence of membranes, and thick meconium-stained amniotic fluid.

In the operating theatre, an 18 G intravenous cannula was inserted, and Ringer's lactate infusion was started. Standard monitoring was applied, including ECG, non-invasive blood pressure, pulse oximetry, and end-tidal CO₂. Premedication was administered with glycopyrrolate 0.2 mg and ondansetron 4 mg. Anaesthetic induction was achieved using propofol 120 mg, and rapid sequence intubation was facilitated with succinylcholine 100 mg. A size 7 endotracheal tube was successfully inserted. Anaesthesia was maintained with a mixture of oxygen, nitrous oxide, atracurium, and sevoflurane. Following delivery of the baby, 100 μ g fentanyl was administered to provide postoperative analgesia. Intraoperative haemodynamic monitoring demonstrated stable parameters throughout the procedure. At the conclusion of the surgery, neuromuscular blockade was reversed using neostigmine 2.5 mg and glycopyrrolate 0.4 mg, and the patient was transferred to the postanaesthetic care unit, where her recovery was uneventful.

DISCUSSION

The anaesthetic management of parturients with NF1 requires a comprehensive understanding of the disorder's multi system involvement [1]. NF1 primarily manifests with cutaneous lesions; however, the presence of neurofibromas in the oropharyngeal region may complicate airway management, especially during emergency interventions [1-3]. In this patient, the airway evaluation revealed a Mallampati Grade III classification, which may be associated with a difficult laryngoscopy [4]. Despite this, the absence of palpable masses and the presence of adequate mouth opening were reassuring. Nonetheless, anticipation of potential difficulties led to the decision to perform a rapid sequence induction with succinylcholine, thereby minimising the risk of aspiration and securing the airway promptly [5].

Preeclampsia further complicates the management by introducing haemodynamic instability and an increased risk of end-organ dysfunction [6]. The patient's blood pressure was moderately elevated, and careful monitoring during induction and maintenance was crucial. In such cases, the choice of induction agents must consider both the rapidity of action and the potential impact on maternal cardiovascular stability. (6) Propofol was selected for its rapid onset and favourable haemodynamic profile, while succinylcholine ensured rapid airway control. Maintenance with a combination of inhalational agents and a muscle relaxant (atracurium) provided a balanced anaesthetic technique, allowing for stable intra-operative conditions.

The literature suggests that patients with NF1 may exhibit increased sensitivity to non-depolarising neuromuscular blocking drugs, which necessitates cautious dosing and vigilant monitoring of neuromuscular function [1]. In this case, atracurium was used in a single loading dose without any observed prolonged effect or adverse reactions, indicating an appropriate response in this patient. Moreover, the administration of fentanyl post-delivery provided effective analgesia without compromising the neonate's condition.

An important aspect of this case was the multidisciplinary approach required in the management of a preeclamptic parturient with NF1. Close communication among the obstetricians, anaesthesiologist's, and nursing staff ensured that all potential complications were anticipated and arrangements were made to manage them promptly. The decision to proceed with general anaesthesia, despite the potential for regional techniques in NF1, was based on the emergent nature of the delivery and the need for rapid control of the airway in the setting of foetal distress. This case reinforces the importance of individualised anaesthetic planning, where each component of the patient's condition- from airway assessment to haemodynamic stability- is carefully evaluated.

A review of similar published cases reveals consistent challenges in the anaesthetic management of parturients with NF1. Govaerts N et al., described anaesthetic considerations for parturients with NF1, emphasising airway assessment and the potential for increased sensitivity to neuromuscular blocking agents [1]. Case reports by several authors have documented successful management of preeclamptic parturients with NF1 using both regional and general anaesthetic techniques, with the choice largely depending on the urgency of delivery and the presence of oropharyngeal neurofibromas [Table/Fig-7]. Saini S et al., reported a case where regional anaesthesia was successfully employed in a non-emergency setting, highlighting the feasibility of this approach when time permits thorough evaluation [7]. Similar to our case, Kumar N et al., described a patient where general anaesthesia was preferred due to emergency conditions and concerns about potential airway complications [8]. Magalhães E et al., documented a case of a parturient with Von Recklinghausen's disease where anaesthetic challenges included difficult airway management and cardiovascular complications [9]. Additionally, Süleyman Deniz M et al., emphasised the importance of thorough preoperative assessment in pregnant patients with neurofibromatosis to anticipate potential complications [10]. The management approaches across these cases demonstrate the necessity of individualised assessment and preparation for potential complications. A comparative analysis of anaesthetic challenges and management strategies in our case with those previously published in the literature is presented in [Table/Fig-7] [1,7-10].

Study	Patient details	Anaesthetic challenges	Anaesthetic approach	Outcome
Present case	27-year-old primigravida with preeclampsia and NF1	Mallampati Grade III, emergency situation, preeclampsia	General anaesthesia with rapid sequence induction	Uneventful
Govaerts N et al., [1]	Parturient with NF1	Potential difficult airway, increased sensitivity to neuromuscular blockers	Tailored approach based on airway assessment	Successful
Saini S et al., [7]	Preeclamptic parturient with Von Recklinghausen's neurofibromatosis	Hypertension, potential difficult airway	Regional anaesthesia	Uneventful
Kumar N et al., [8]	Pregnant patient with NF1	Multiple neurofibromas, potential airway difficulty	General anaesthesia	Successful
Magalhães E et al., [9]	Parturient with Von Recklinghausen's disease	Difficult airway, cardiovascular complications	Individualised approach	Successful with challenges
Süleyman Deniz M et al., [10]	Pregnant patient with neurofibromatosis	Multiple system involvement	Careful preoperative assessment and planning	Successful

[Table/Fig-7]: Comparison of anaesthetic challenges and management strategies in parturients with NF1 [1,7-10].

Furthermore, the preoperative laboratory investigations provided essential information regarding the patient's baseline status, confirming that no major abnormalities were present aside from the proteinuria associated with preeclampsia. This allowed the anaesthetic team to proceed with confidence, knowing that electrolyte imbalances or haematological issues were unlikely to complicate the intraoperative course. The use of a standardised table comparing normal Indian values with the patient's results further facilitated a clear understanding of the patient's clinical condition.

CONCLUSION(S)

This case report highlights the complexities involved in the anaesthetic management of a preeclamptic parturient with NF-I. Despite the potential challenges posed by the airway and cardiovascular system, careful preoperative assessment and a well-considered anaesthetic plan allowed for a successful general anaesthetic approach. The patient experienced a stable intra-operative course and an uneventful recovery. This case underscores the necessity for anaesthesiologists to remain vigilant and to tailor their management strategies to address the unique challenges presented by multi-system disorders such as NF1, particularly in the emergency obstetric setting.

REFERENCES

[1] Govaerts N, Roofthoof E, De Velde M Van. Anaesthetic considerations for the parturient with neurofibromatosis type 1. *Acta Anaesthesiol Belg.* 2024;75(Suppl. 1):115-23.

[2] Okazaki Y, Ichiba T, Fujisaki N. Potential fatal complication of neurofibromatosis type 1: Acute upper airway obstruction due to ruptured transverse cervical artery aneurysm. *Cureus.* 2022;14(12):e32910.

[3] Sarkar S, Seth C, Dutta M, Bandyopadhyay SN. Solitary isolated oropharyngeal neurofibroma presenting with dysphagia in the setting of Von Recklinghausen's disease. *Ear Nose Throat J.* 2024;1455613241249022. Doi: 10.1177/01455613241249022.

[4] Yemam D, Melese E, Ashebir Z. Comparison of modified mallampati classification with Cormack and Lehane grading in predicting difficult laryngoscopy among elective surgical patients who took general anaesthesia in Werabie comprehensive specialized hospital - cross sectional study. *Ethiopia.* 2021. *Ann Med Surg.* 2022;79:103912.

[5] Tran DTT, Newton EK, Mount Vah, Lee JS, Wells GA, Perry JJ. Rocuronium versus succinylcholine for rapid sequence induction intubation. *Cochrane Database Syst Rev.* 2015;2015(10):CD002788.

[6] Bourke E, Gatenby PB. Renal artery dysplasia with hypertension in neurofibromatosis. *Br Med J.* 1971;3:681-82.

[7] Saini S, Sachdev N, Kumar H, Sharma M. Anaesthetic consideration in a pre-eclamptic parturient with Von Recklinghausen's neurofibromatosis. *J Obstet Anaesth Crit Care.* 2014;4(1):33-35.

[8] Kumar N, Sachdev Ms, Gulati A, Singh P. Anaesthetic consideration in patient with neurofibromatosis type 1 in pregnancy. *Int J Health Sci Res.* 2015;5(8):573-76.

[9] Magalhães E, Gomes M, Barra GB, Souza TG, Sousa JA, Sakata RK. Anaesthetic hitches and management in a parturient with Von Recklinghausens disease. *BMJ Case Rep.* 2023;16(8):e254688.

[10] Süleyman Deniz M, Alagoz A, Tugrul M. Anaesthesia management in a pregnant patient with neurofibromatosis. *J Surg Med.* 2021;5(5):498-500.

PARTICULARS OF CONTRIBUTORS:

1. Assistant Professor, Department of Anaesthesiology, Smt. Bhikhiben Kanjibhai Shah Medical Institute and Research Centre, Sumandeep Vidyapeeth (Deemed to be University), Vadodara, Gujarat, India.
2. Professor, Department of Anaesthesiology, Narendra Modi Medical College, L.G. Hospital, Ahmedabad, Gujarat, India.
3. Professor and Head, Department of Anaesthesiology, Smt. Bhikhiben Kanjibhai Shah Medical Institute and Research Centre, Sumandeep Vidyapeeth (Deemed to be University), Vadodara, Gujarat, India.

NAME, ADDRESS, E-MAIL ID OF THE CORRESPONDING AUTHOR:
Charmi Hitenbhai Shah,
20, Netaji Society, Opp. Muktanand, Karelibaug, Vadodara-390018, Gujarat, India.
E-mail: charmi28shah@gmail.com

AUTHOR DECLARATION:

- Financial or Other Competing Interests: None
- Was informed consent obtained from the subjects involved in the study? Yes
- For any images presented appropriate consent has been obtained from the subjects. Yes

PLAGIARISM CHECKING METHODS: [Jain H et al.] ETYMOLOGY: Author Origin

- Plagiarism X-checker: Mar 13, 2025
- Manual Googling: May 01, 2025
- iThenticate Software: May 03, 2025 (9%)

EMENDATIONS: 5

Date of Submission: Mar 10, 2025
Date of Peer Review: Apr 04, 2025
Date of Acceptance: May 05, 2025
Date of Publishing: Jun 01, 2025